

Case Report

Kimura's Disease: A Rare Cause of Nephrotic Syndrome with Lymphadenopathy

Siti Kamariah OTHMAN¹, Kamaliah MOHD DAUD¹,
Nor Hayati OTHMAN²

Submitted: 12 Dec 2010

Accepted: 14 Apr 2011

¹ Department of Medicine, Hospital Universiti Sains Malaysia, 16150 Kubang Kerian, Kelantan, Malaysia

² Department of Pathology, Hospital Universiti Sains Malaysia, 16150 Kubang Kerian, Kelantan, Malaysia

Abstract

Kimura's disease is a rare condition and typically presents as non-tender subcutaneous swellings in the head and neck region, usually in the pre-auricular and submandibular areas. It is associated with lymphadenopathy (both local and distal), marked peripheral eosinophilia, and an elevated IgE level. It can easily be mistaken for a malignant disorder. Fine needle aspiration can be misleading, and a diagnosis is established only by histopathological examination. Renal involvement, which may affect up to 60% of patients, is the only systemic manifestation. We report a case of Kimura's disease in a Malay patient who was associated with steroid-responsive nephrotic syndrome.

Keywords: eosinophilic granuloma of soft tissue, Kimura's disease, lymphadenopathy, neck, nephrotic syndrome

Introduction

Kimura's disease is a benign, chronic inflammatory soft tissue disorder of unknown origin. Although it is rare, most cases of Kimura's disease have originated in China, Japan, or Southeast Asia, and the disease is uncommon in Caucasians and rare in Africans. There is a marked male predominance. The peak age of onset is during the third decade of life.

Kimura's disease was first described in 1937 in the Chinese literature by HT Kimm and C Szeto and initially was recognised as "eosinophilic hyperplastic lymphogranuloma". The definitive histological description was published by Kimura et al. (1) in 1948, and thus, the disease has borne the author's name. Since that time, there has been a gradual increase in the number of reports of the disease.

Case Report

A 40-year-old Malay male first presented in August 2005 with generalised body oedema of 2 weeks' duration. He was previously well, without any history of hospitalisation. He reported multiple painless right neck swellings for the last 30 years, which were gradually increasing in size and were not associated with any local or systemic symptoms. There was no history of chronic cough,

prolonged fever, reduced weight, night sweats, or low back pain suggestive of tuberculosis (TB) infection. There was no family history of renal or autoimmune disease.

Examination revealed a normotensive man with bilateral gross leg oedema and ascites. Three cervical lymph nodes were palpable at the posterior triangle of the right neck, the largest being 2 cm in diameter. The lymph nodes were firm, non-matted, non-tender, smooth surfaced, and mobile. There was also a cystic lesion located behind the right ear, measuring 2 × 2 cm, non-tender, and mobile. His lungs were clear. There was no hepatosplenomegaly and no other palpable regional lymph nodes.

Investigations revealed a haemoglobin level of 14.6 g/dL, a white cell count of 10.47×10^9 cells/L with 8.7% eosinophils, and a normal platelet count. Urinalysis revealed 4+ albuminuria and nil for sugar and red blood cells. The patient's 24-hour total urinary protein excretion was 8.11 g, and his serum creatinine level was 149 μ mol/L. Electrolyte levels were normal. Albumin and globulin concentrations were 16 g/L and 24 g/L, respectively. The erythrocyte sedimentation rate was 89 mm/hour, and total cholesterol level was 19.6 mmol/L. The Mantoux test was negative. Sputum samples for direct smear were negative. Sputum culture for *Mycobacterium* was still pending at that time.

The tests for hepatitis B surface antigen and anti-hepatitis C virus antibody were negative. The antinuclear factor and rheumatic factor tests were negative, and complement C3 and C4 levels were within normal limits. The antistreptolysin titre was negative. Ultrasound examination showed normal-sized kidneys with increased echogenicity on the right kidney, and no calculus was seen. A chest radiograph did not show any abnormal opacities, cavitations, or perihilar lymph nodes.

A biopsy of the lymph nodes showed haemorrhage and hyperplastic lymphoid follicles with germinal centres. The paracortical areas showed eosinophilic infiltrate and proliferation of post-capillary venules (Figure 1). No evidence of malignancy or metastatic deposits was observed. The findings were consistent with Kimura's disease. Renal biopsy was not performed in this patient because of his refusal.

The patient was started on prednisolone (1 mg/kg/day) and diuretics. Subsequently, his serum creatinine level reduced to 107 $\mu\text{mol/L}$. He was then discharged on oral prednisolone (80 mg once daily), oral furosemide (40 mg twice daily), and oral atorvastatin (20 mg once daily).

All the enlarged right cervical lymph nodes shrunk after prednisolone treatment was initiated. The sputum culture that was taken during his first admission (August 2005) yielded *Mycobacterium tuberculosis*, which was sensitive to isoniazid, streptomycin, rifampicin, and ethambutol. The patient was started on an anti-TB drug regime that consisted of ethambutol, isoniazide, rifampicin, pyrazinamide (EHRZ) in February 2006. Prednisolone prescription was continued together with the anti-TB drugs. He had a history of relapsed nephrotic syndrome in June 2006 while on a tapering dosage of prednisolone.

From July 2007 until the present, his nephrotic syndrome was in remission. His serum creatinine level was 120 $\mu\text{mol/L}$ (static), total cholesterol level was 4.70 mmol/L, and serum albumin level was 44 g/dL. His cervical lymph nodes were also resolved. He is currently on maintenance prednisolone (5 mg once daily), oral enalapril (5 mg once daily), and oral atorvastatin (20 mg once daily).

Discussion

Our patient was a 40-year-old male of Malay ethnicity who developed nephrotic syndrome 30 years after the onset of lymphadenopathy, which is the longest such duration compared with previous reported cases. His eosinophil count was only at a borderline elevated level (8%) on initial

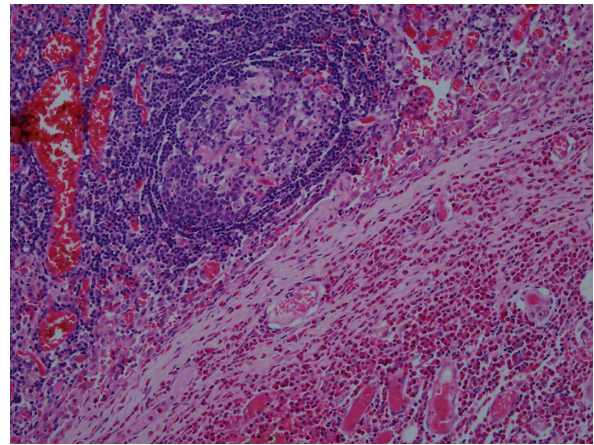


Figure 1: The paracortical areas show eosinophilic infiltration and proliferation of post-capillary venules. No evidence of malignancy or metastatic deposits is seen (200 \times magnification).

presentation, and peripheral eosinophilia is the most consistent feature in most cases of Kimura's disease.

The differential diagnosis of nephrotic syndrome associated with lymphadenopathy in this patient included lymphoma, especially Hodgkin's lymphoma. Minimal change disease was found in Hodgkin's lymphoma associated with nephrotic syndrome. However, the lymph node biopsy was not suggestive of lymphoma in this case, and the patient did not have constitutional symptoms consistent with lymphoma. Membranous nephropathy has also been associated with TB. Even though the patient's sputum smear was subsequently positive for TB, the initial lymph node biopsy did not suggest TB lymphadenitis. Acute or chronic lymphocytic leukemias can also be associated with nephrotic syndrome, typically minimal change disease, but both were unlikely in this patient because he had a normal blood count and the lymphadenopathy was longstanding and confined only to the neck region.

Until 1982, 21 cases of nephropathy in patients with Kimura's disease had been reported in the literature, and all involved male patients (2). A subsequent review covering the period from 1981 to 1998 revealed an additional 12 cases, 10 of which involved male patients (3). A search by Yuen et al. (5) of the English medical literature from 1998 to 2004 revealed 8 more cases of Kimura's disease with nephropathy. The patients were 9 to 35 years of age and were males.

The renal manifestations of Kimura's disease are as membranous glomerulonephritis, minimal change glomerulonephritis, diffuse proliferative glomerulonephritis, mesangial proliferative glomerulonephritis, and nephritic syndrome (4,6). In our patient, the type of renal involvement could not be ascertained because he refused renal biopsy. It is intuitive to speculate that male gender is a risk factor for renal involvement in Kimura's disease, but a conclusion cannot yet be reached given the small number of reported cases (5).

Management strategies range from conservative observation for asymptomatic patients to surgical excision, steroid therapy, or radiotherapy for symptomatic patients (4), but no method has been proven to be the best, and recurrence is common. Steroids, for example, are effective in inducing remission of subcutaneous masses and lymphadenopathy in Kimura's disease, but relapse may occur when treatment is stopped (7). Several reports describing a steroid-responsive nephrotic syndrome have shown a reduction in the size of subcutaneous nodules with steroids, implying a common aetiopathogenesis of the renal lesion and Kimura's disease. The nephrotic syndrome in our patient was steroid responsive, and his enlarged lymph nodes also resolved after steroid therapy. His nephrotic syndrome, however, relapsed while on a tapering dose of prednisolone, and he had to be maintained on a low-dose steroid. Radiotherapy could be a highly effective alternative when other treatment modalities are unsuccessful (8). In summary, Kimura's disease should be considered as a differential diagnosis in male Asian patients with proteinuria or nephrotic syndrome associated with lymphadenopathy.

Optimal treatment regimens and long-term prognosis for renal lesions in patients with Kimura's disease are largely unknown due to the rarity of these lesions and the lack of long-term follow-up data in the literature. There is no evidence that nephropathy in Kimura's disease carries an exceptionally poor outcome.

Authors' Contributions

Analysis and interpretation of data: NHO
Drafting of the article: SKO
Critical revision of the article: KMD

Correspondence

Dr Siti Kamariah Othman
MD (USM)
Department of Medicine
Level 7, Hospital Universiti Sains Malaysia
16150 Kubang Kerian
Kelantan, Malaysia
Tel: +6013-709 6579
Email: dr_pegaga@yahoo.com.my

References

1. Kimura T, Yoshimura S, Ishikawa E. On the unusual granulation combined with hyperplastic changes of lymphatic tissue. *Trans Soc Pathol.* 1948;**37**: 179–180.
2. Yamada A, Mitsuhashi K, Miyakawa Y, Kosaka K, Takehara K, Iijima M, et al. Membranous glomerulonephritis associated with eosinophilic lymphofolliculosis of the skin (Kimura's disease): Report of a case and review of the literature. *Clin Nephrol.* 1982;**18**(4):211–215.
3. Natov SN, Strom JA, Ucci A. Relapsing nephrotic syndrome in a patient with Kimura's disease and IgA glomerulonephritis. *Nephrol Dial Transplant.* 1998;**13**(9):2358–2363.
4. Messina-Doucet MT, Armstrong WB, Allison G, Pena F, Kim JKV. Kimura's disease: Two case reports and a literature review. *Ann Otol Rhinol Laryngol.* 1998;**107**(12):1066–1071.
5. Yuen SK, Yong SP, Tsui WMS, Siu FY, Tsui HS, Cheung KO. Minimal change nephrotic syndrome with IgM deposits in Kimura's disease: A case report and literature review. *Hong Kong J Nephrol.* 2004;**6**(2):97–102.
6. Hui PK, Chan JK, Ng CS, Kung IT, Gwi E. Lymphadenopathy of Kimura's disease. *Am J Surg Pathol.* 1989;**13**(3):177–186.
7. Nakahara C, Wada T, Kusakari J, Kanemoto K, Kinugasa H, Sibasaki M, et al. Steroid-sensitive nephrotic syndrome associated with Kimura disease. *Pediatr Nephrol.* 2000;**14**(6):482–485.
8. Kileksiz S, Calli C, Eski E, Topcugil F, Bener S. Radiotherapy for Kimura's disease: Case report and review of the literature. *J BUON.* 2007;**12**(2): 277–280.