

G KRISHNA KUMAR

Submitted: 25 May 2011

Accepted: 18 Jul 2011

Pediatric Surgical Unit, Department of Surgery, Hospital Tengku Ampuan Afzan, 25100 Kuantan, Pahang, Malaysia

Abstract

In an infant presenting with a mass in the abdomen and non-bilious vomiting, duplication cyst needs to be considered in the list of differential diagnoses. Gastric duplication cyst is an uncommon occurrence in children. Diagnosis is based on clinical findings and imaging features. Surgical excision is safe and offers a complete cure. The literature recommends excision even in asymptomatic cases due to isolated reports of malignancy arising in the duplication cyst in later life.

Keywords: abdominal neoplasms, cyst, differential diagnosis, gastrointestinal tract, paediatrics, vomiting

Introduction

Vomiting in a child can occur due to various conditions. In the setting of an abdominal mass combined with vomiting, the aetiology is likely a surgical problem. Duplication cysts of the alimentary tract can present with the above features. The gastric duplication (GD) cyst in particular is an uncommon lesion, accounting for 4% of gastrointestinal tract duplications (1). To qualify as a duplication cyst, the following criteria need to be satisfied: lining with the gastrointestinal mucosa, attachment to the gastrointestinal tract, and the presence of a smooth muscle coat (2).

This case report outlines the presentation and management of a GD cyst.

Case Series

A 10-month-old baby girl presented with non-bilious vomiting and an abdominal mass that had been present for 2 weeks. The child was otherwise well. On examination, there was a large, firm, non-tender mass, which moved with respiration, on the right side of the abdomen. The child was well hydrated and was unremarkable upon systemic examination.

A cystic mass was identified on an ultrasound scan. Computed tomography contrast showed a cystic swelling associated closely to bowel mesentery (Figure 1). A possible diagnosis of mesenteric cyst was made. A cystic mass that was 8 × 6 cm in size, dumbbell-shaped, and arising from the greater curvature of the stomach, consistent with a cystic duplication (Figure 2), was excised extramucosally without gastric resection. A gastric lining in which all of the layers of the

gastro-intestinal tract had a typical appearance was identified on histology, confirming GD cyst (Figure 3).

The child was discharged on post-operative day 4 and was well at the 6-month follow-up.

Discussion

The stomach ranks next to the small bowel and the oesophagus in the order of occurrence of gastrointestinal tract duplications. Depending on the location, the presentation varies from gastric outlet obstruction to asymptomatic occurrence (3). Pancreatitis has been reported to occur in the uncommon event of communication of the lesion with the pancreas (4). Of note is the acute presentation that can result from bleeding or perforation (5).

Most GD cysts present in infancy and infrequently in age extremes—in utero and among the elderly (6,7). It is supposedly more common in females. The baby girl in our case fits the epidemiology (8).

Contrast study may reveal indentation on the gastric wall, making identification possible (9). Computed tomography or magnetic resonance imaging can help to localise the cyst to its origin, but may not always, as in our case. Plain radiography of the abdomen may sometimes present findings suggestive of GD cyst, including soft-tissue interposition between the gastric shadow and transverse colon (10). Uncommon associations of GD cyst include lung sequestration and multicystic kidney (11,12). Extramucosal excision with preservation of the adjacent gastric wall is recommended, as was performed in our case. Surgical options include laparoscopic

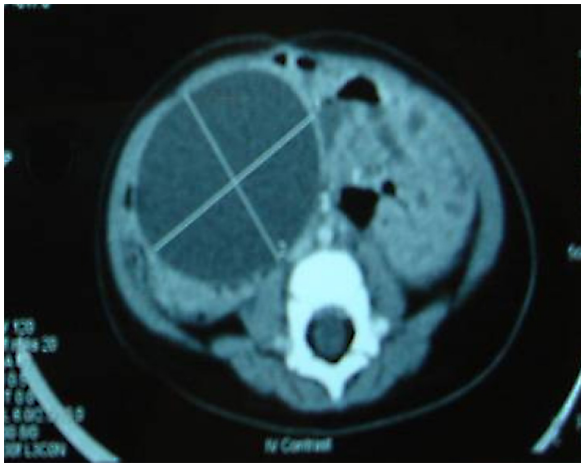


Figure 1: Abdominal computed tomography showing cystic mass occurring close to the bowel mesentery.

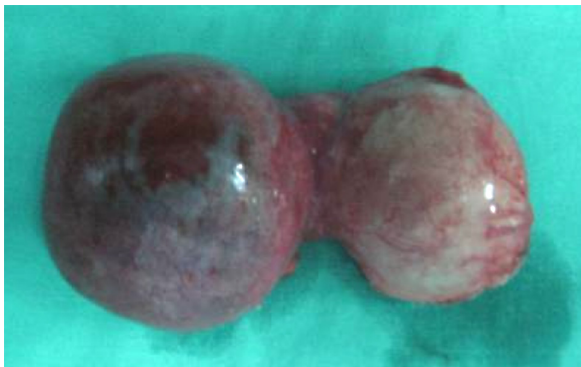

Figure 2: Dumbbell-shaped gastric duplication cyst.

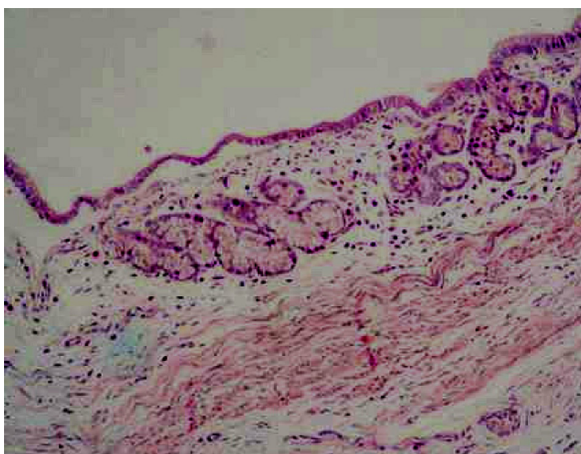


Figure 3: Single-layer columnar epithelium with underlying gastric mucosal glands (haematoxylin and eosin staining, 200× magnification).

excision and the endoscopic approach, depending on the expertise of the surgeons and location of the lesion (13,14). The dumbbell appearance of the gastric duplication in our case was unique and had not been described in the literature. In asymptomatic cases, excision is recommended due to the possible development of tumours such as adenocarcinoma or carcinoid in the GD cyst (15).

Antenatal diagnosis is sometimes possible, enabling expectant management in the post-natal period after appropriate evaluation. Occurrence in the thoracic region has been documented as a rare finding. The embryological aetiology is proposed to be due to faulty separation of the notochord from the endoderm resulting in enteric duplications (16,17).

The diagnosis of GD cyst is to be kept in mind during evaluation of an infant with an abdominal mass and vomiting. Imaging may be helpful but is not confirmatory. Excision with gastric preservation is usually possible, offering a complete cure.

Acknowledgement

The contributions of Dr Mubarak M, consultant radiologist, Hospital Kuantan, and Dr Kalavathy R, consultant pathologist, Hospital Kuantan, are thankfully acknowledged.

Correspondence

Dr G Krishna Kumar
MRCS Ed, MCh (Pediatric Surgery), FEBPS
Pediatric Surgical Unit
Department of Surgery
Hospital Tengku Ampuan Afzan
25100 Kuantan
Pahang, Malaysia
Tel: +609-513 3333
Email: sasisang@rediffmail.com

References

1. Pruksapong C, Donovan RJ, Pinit A, Heldrich FJ. Gastric duplication. *J Pediatr Surg.* 1979;**14**(1): 83–85.
2. Bower RJ, Sieber WK, Kiesewetter WB. Alimentary tract duplications in children. *Ann Surg.* 1978;**188**(5):669–674.
3. Carachi R, Azmy A. Foregut duplications. *Pediatr Surg Int.* 2002;**18**(5–6):371–374.
4. Katz W, Annessa G, Read RC. Gastric duplication with pancreatic communication. Presenting as pancreatitis. *Minn Med.* 1967;**50**(8):1175–1179.

5. Stephen TC, Bendon RW, Nagaraj HS, Sachdeva R. Antral duplication cyst: A cause of hypergastrinemia, recurrent peptic ulceration, and hemorrhage. *J Pediatr Gastroenterol Nutr*. 1998;**26(2)**:216–218.
6. Bidwell JK, Nelson A. Prenatal ultrasonic diagnosis of congenital duplication of the stomach. *J Ultrasound Med*. 1986;**5(10)**:589–591.
7. Shaw RC. Cyst formation in relation to stomach and esophagus. *Br J Surg*. 1951;**39(155)**:254–257.
8. Sieunarine K, Manmohansingh E. Gastric duplication cyst presenting as an acute abdomen in a child. *J Ped Surg*. 1989;**24(11)**:1152.
9. Lima M, Grandi M, Ruggeri G, Cacciari A, Domini M, Tani G. Gastric duplication cyst in a child treated by extra mucosal excision. *Pediatr Surg Int*. 1992;**7**:206–208.
10. Barlev DM, Weinberg G. Acute gastrointestinal hemorrhage in infancy from gastric duplication: Imaging findings. *Emerg Rad*. 2004;**10(4)**:204–206.
11. Mahour GH, Woolley MM, Payne VC Jr. Association of pulmonary sequestration and duplication of the stomach. *Int Surg*. 1971;**56(4)**:224–227.
12. Liebert PS. Gastric duplication and multicystic kidney associated with gonadal dysgenesis. *Clin Pediatr (Phila)*. 1970;**9(1)**:60–62.
13. Machado MA, Santos VR, Martino RB, Makdissi F, Canedo L, Bacchella T, et al. Laparoscopic resection of gastric duplication: Successful treatment of a rare entity. *Surg Laparosc Endosc Percutan Tech*. 2003;**13(14)**:268–270.
14. Stecevic V, Karim R, Jacobs R. Gastric duplication cyst treated by endoscopic electrosurgical snare resection. *Gastrointest Endosc*. 2003;**57(4)**:615–616.
15. Mayo HW Jr, McKee EE, Anderson RM. Carcinoma arising in reduplication of the stomach (gastrogenous cyst): A case report. *Ann Surg*. 1955;**141(4)**:550–555.
16. Daher P, Karam L, Riachy E. Prenatal diagnosis of an intrathoracic gastric duplication: A case report. *J Ped Surg*. 2008;**43(7)**:1401–1404.
17. Koklu E, Akcakus M, Okur H, Basbug M, Patiroglu T, Yikilmaz A, et al. Gastroenteric duplication cysts in a newborn: Unusual clinical and radiologic presentations. *Pediatr Dev Pathol*. 2008;**11(1)**:66–67.