

Simultaneous Non-Traumatic Perforation of the Right Hepatic Duct and Gallbladder: An Atypical Occurrence

Pankaj Kumar GARG¹, Bhupendra Kumar JAIN¹, Satya Deo PANDEY¹, Vinita RATHI², Amarendra Singh PURI³

Submitted: 5 Dec 2011
Accepted: 8 Feb 2012

¹ Department of Surgery, University College of Medical Sciences and Guru Teg Bahadur Hospital, University of Delhi, Delhi 110095, India

² Department of Radiodiagnosis, University College of Medical Sciences and Guru Teg Bahadur Hospital, University of Delhi, Delhi 110095, India

³ Department of Gastroenterology, Maulana Azad Medical College and Govind Ballabh Pant Hospital, Delhi 110095, India

Abstract

Simultaneous non-traumatic perforation of the extrahepatic bile duct and the gallbladder is an uncommon occurrence that has been infrequently reported. We describe a patient with a spontaneous perforation of both the extrahepatic bile duct and the gallbladder. A contrast-enhanced computed tomography (CECT) scan of the abdomen and endoscopic retrograde cholangiopancreatography (ERCP) demonstrated a perforation of the gallbladder and a free leak from the right hepatic duct, respectively. Endoscopic biliary drainage following a sphincterotomy and biliary stent placement led to a dramatic improvement in the patient's general condition. He was subsequently scheduled to undergo an elective cholecystectomy. Repeat ERCP performed at 4 weeks after the initial stenting showed a normal cholangiogram and a distally migrated stent, which was there after removed. However, early stent removal led to re-perforation of hepatic duct and gallbladder. A repeat endoscopic biliary drainage did not help, and the patient developed biliary peritonitis. Surgical exploration revealed a perforation at the fundus of the gallbladder, 400 ml of biliopurulent collection and a frozen Calot's triangle. A subtotal cholecystectomy, gall stone removal, and a thorough peritoneal lavage were undertaken. The patient improved postoperatively. The second biliary stent was removed after 4 months. This case report highlights the role of endoscopic biliary drainage in the management of an extrahepatic bile duct perforation and warns against the early removal of a biliary stent.

Keywords: CT scan, ERCP, gallbladder, hepatic duct, perforation

Introduction

A non-traumatic perforation of the biliary tract is a rare occurrence that commonly involves the gallbladder. Only a few case reports have described a non-traumatic perforation of the extrahepatic bile duct, and most have been observed in neonates and children due to congenital anomalies. Since the first description of a non-traumatic perforation of the extrahepatic bile duct, only 70 cases have been reported in the English literature (1). The probable causes include high intra-ductal pressure due to obstruction of the ampulla by a tumour or calculus, pregnancy, and necrosis of the duct wall secondary to vascular thrombosis (2). To the best of our knowledge, a simultaneous non-traumatic perforation of the extrahepatic bile

duct and gallbladder has not yet been reported. We present a case of a simultaneous non-traumatic perforation of the extrahepatic bile duct and gallbladder in a 45-years-old man and discuss its management.

Case Report

A 45-years-old man who was a resident of Delhi and a street vendor by profession, presented with pain in the right upper abdomen, jaundice, and fever of 15 days duration. There was no past history suggestive of biliary colic, or jaundice. A physical examination revealed tachycardia (104 min), icterus and a tender right hypochondrial lump that was continuous with the liver. His serological parameters were as follows: hemoglobin, 7.2 gm%; total

leukocyte count, 29, 100 mm³; total bilirubin, 30.3 mg% (direct, 18.3 mg%); alkaline phosphatase, 1086 IU; and prothrombin time, 2.3 (INR). Contrast-enhanced computed tomography (CECT) of the abdomen supplemented with ultrasonography (USG) demonstrated hepatomegaly (14.7 cm). The gallbladder was grossly distended (Figure 1). A hypodense pericholecystic collection was observed communicating with the gallbladder at the level of its fundus on the right side, suggesting gallbladder perforation (Figure 2). The distended gallbladder and the pericholecystic collection appeared to compress the confluence of the right and left hepatic ducts and the common hepatic duct. Upstream dilatation of the right and left hepatic ducts and dilatation of the intra-hepatic biliary radicles were also observed. A calculus was floating in the body of the gallbladder. Free fluid was not present in the paracolic gutters or pelvis. The patient underwent endoscopic retrograde cholangiopancreatography (ERCP), which demonstrated that the entire length of the common bile duct was compressed by an extrinsic mass, with a free leak of contrast media from the right hepatic duct (Figure 3). The common bile duct (CBD) was free of stones. A guide wire was placed across the site of the leak into the right hepatic duct. A 7 Fr, 12 cm stent was placed with the proximal end above the site of the leak. Endoscopic biliary drainage led to a dramatic improvement in the patient's general condition with gradual resolution of the lump and the jaundice. The pericholecystic collection disappeared after 4 days, as confirmed upon repeat USG. The patient was scheduled for an elective cholecystectomy. His serum bilirubin decreased from the initial value of 30.3 mg% to a plateau averaging 5.0 mg% after 4 weeks. CECT of the abdomen showed distal migration of the biliary stent, which abutted the lateral wall of the duodenum. There was mild intrahepatic biliary radicle dilatation. A repeat ERCP was undertaken, which showed a normal biliary tract; the stent was removed. Unfortunately, 2 days later, the patient developed severe pain in the right upper abdomen. An examination revealed a tender, firm right hypochondrial lump. A repeat abdominal ultrasound showed gallbladder thickening with a small pericholecystic collection. The common duct was not visualised clearly. A repeat ERCP demonstrated a free leak of contrast from the right hepatic duct. A guide wire was placed across the site of the leak into the right hepatic duct and a 7 Fr, 12 cm stent was placed with the proximal end above

the site of the leak. However, this time, the patient did not respond well and developed biliary peritonitis. Surgical exploration revealed a perforation at the fundus of the gallbladder, 400 ml of biliopurulent collection and a frozen Calot's triangle. A subtotal cholecystectomy, gall stone removal and a thorough peritoneal lavage

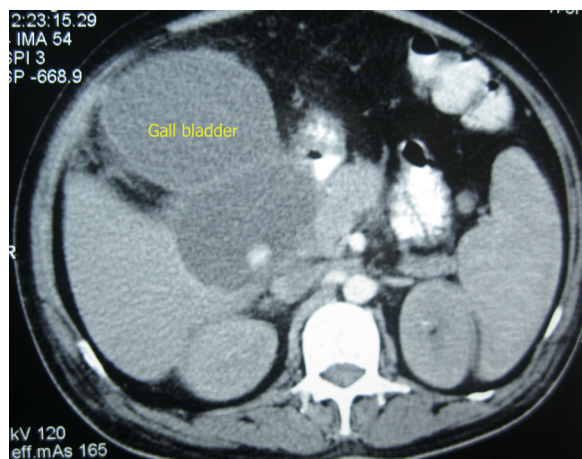


Figure 1: An axial section of an abdominal contrast-enhanced computed tomography showing a distended gallbladder. A large calculus is observed in the lumen of the gallbladder (sonographic correlation).

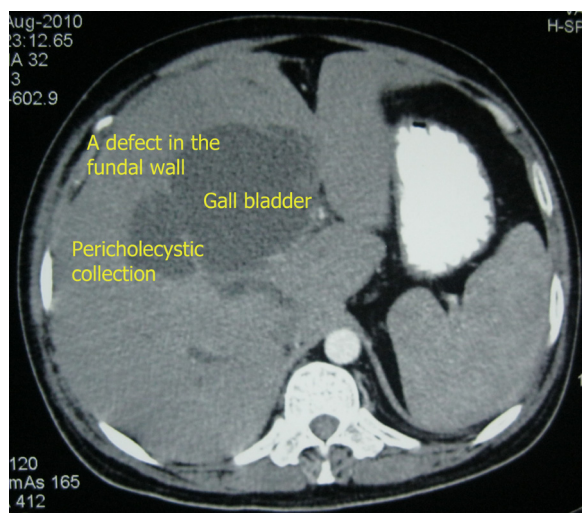


Figure 2: An axial section of an abdominal contrast-enhanced computed tomography showing a defect in the fundus of the gallbladder with a communication to a pericholecystic collection.

were undertaken. The patient improved and progressed well. The subhepatic drain stopped draining bile on the 10th day and was removed on the 12th day following surgery. ERCP performed after 16 weeks revealed a normal biliary tract, and the stent was removed. The patient was asymptomatic after 7 months of follow up. A histopathological examination of the gallbladder demonstrated chronic cholecystitis.

Discussion

Various approaches for the management of bile duct perforations have been described, but these approaches need to be tailored according to the general condition of the patient, the extent of the peritonitis, and the imaging findings. Patients presenting with generalised peritonitis require surgical exploration, thorough lavage and drainage of the peritoneal cavity, a sutured closure of the perforation, if possible, and treatment of any associated biliary pathology. Most of these patients have associated choledocholithiasis, which may require either a choledocholithotomy with T-tube drainage (3) or a choledochoduodenostomy (4). A perforation

may also be closed over a T-tube if there is no associated biliary pathology (5). Suture repair may not be possible if severe inflammation is present at the perforation site. A more proximal perforation of the hepatic duct may also preclude the feasibility of primary repair. These patients may be managed with biliary decompression with T-tube drainage provided there is no distal obstruction. Patients who have a localised collection may be treated with percutaneous drainage of the collection and endoscopic sphincterotomy with stenting (6). Percutaneous transhepatic gallbladder drainage has been advocated as an initial alternative to surgery to treat gallbladder perforations in high-risk patients (7). The timing of biliary stent removal has been variable in previous reports of bile duct perforation. Bernas et al. (8) reported a case of spontaneous bile duct perforation in a 3-years-old toddler. They managed the case with endoscopic biliary stenting and removed the stent successfully 7 weeks after the procedure. Karvonen et al. (6) waited 3 months for stent removal while successfully managing a case of spontaneous bile duct perforation with endoscopic biliary stenting and percutaneous drainage of a subhepatic collection in a 67-years-old man.

Our patient presented with localised peritonitis in the right hypochondrium and CECT suggested gallbladder perforation and a localised pericholecystic collection causing extrinsic CBD compression with proximal biliary radical dilatation. Although there was a gallbladder perforation, its huge distension may have been caused by a large pericholecystic collection that compressed the entire bile duct and the cystic duct. Due to the significantly abnormal liver function tests, we planned for endoscopic stenting followed by a laparotomy and cholecystectomy. Endoscopic stenting caused a dramatic improvement in the condition of our patient, leading to the postponement of surgical intervention to allow further optimisation of the patient. However, stent removal at 4 weeks led to a re-perforation and biliary peritonitis. This highlights the role of endoscopic drainage in these patients and underscores the importance of delayed removal of the biliary stent.

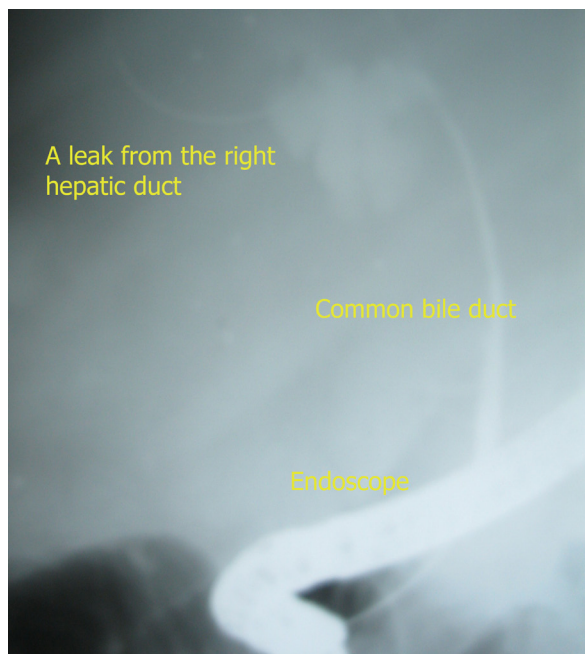


Figure 3: An endoscopic retrograde cholangiopancreatography image showing the entire length of a compressed common bile duct and the free leak of contrast from the right hepatic duct.

Conclusion

We conclude that endoscopic biliary drainage should be considered as an option in the management of non-traumatic perforation of the extrahepatic duct with a caveat that early stent removal may cause re-perforation.

Authors' Contribution

Conception and design: PKG

Acquisition of data: PKG, SP

Analysis and interpretation of data: PKG, BKJ, ASP, VR

Drafting the article: PKG, SP

Critical revision: BKJ, VR, ASP

Final approval of the draft: PKG, BKJ, SP, VR, ASP

Correspondence

Dr Pankaj Kumar Garg

MS General Surgery (India)

DNB General Surgery (India)

Room No. 2207, Ward 22

Department of Surgery

University College of Medical Sciences and Guru Teg

Bahadur Hospital

Dilshad Garden

Delhi 110095, India.

Phone: +91 0112 2692 536

Fax: +91 9868 3996 84

Email dr.pankajgarg@gmail.com

References

1. Kang SB, Han HS, Min SK, Lee HK. Nontraumatic perforation of the bile duct in adults. *Arch Surg.* 2004;**139(10)**:1083–1087.
2. Khanna R, Agarwal N, Singh AK, Khanna S, Basu SP. Spontaneous common bile duct perforation presenting as acute abdomen. *Indian J Surg.* 2010;**72(5)**:407–408.
3. Kobayashi K, Kushida N, Ookubo S, Sano Yoshifumi, Oomori H, Ohashi H, et al. Bile peritonitis due to spontaneous perforation of the left hepatic duct: A case report. *JMAJ.* 2005;**48(8)**:422–425.
4. Marwah S, Sen J, Goyal A, Marwah N, Sharma JP. Spontaneous perforation of the common bile duct in an adult. *Ann Saudi Med.* 2005;**25(1)**:58–59.
5. Mizutani S, Yagi A, Watanabe M, Maejima K, Komine O, Yoshino M, et al. T-tube drainage for spontaneous perforation of the extrahepatic bile duct. *Med Sci Monit.* 2011;**17(1)**:CS8–11.
6. Karvonen J, Gullichsen R, Salminen P, Laine S, Gronroos JM. Successful endoscopic treatment of spontaneous perforation of the common hepatic duct. *Endoscopy.* 2009;**41(Suppl 2)**:E224–5.
7. Huang CC, Lo HC, Tzeng YM, Huang HH, Chen JD, Kao WF, et al. Percutaneous transhepatic gall bladder drainage: A better initial therapeutic choice for patients with gall bladder perforation in the emergency department. *Emerg Med J.* 2007;**24(12)**:836–840.
8. Barnes BH, Narkewicz MR, Sokol RJ. Spontaneous perforation of the bile duct in a toddler: The role of endoscopic retrograde cholangiopancreatography in diagnosis and therapy. *J Pediatr Gastroenterol Nutr.* 2006;**43(5)**:695–697.