

A Simple, Safe, and Effective Surgical Technique for The Treatment of Post-Traumatic Parotid Sialocele

Zamzil Amin ASHA'ARI¹, Mohd Sayuti RAZALI¹, Wan Ishlah LEMAN¹, Ashri AHMAD²

Submitted: 27 Dec 2012

Accepted: 25 Jan 2013

¹ Department of Otolaryngology, Head and Neck Surgery, Faculty of Medicine, International Islamic University Malaysia, Jalan Hospital, 25100 Kuantan, Pahang, Malaysia

² Department of Anaesthesiology and Intensive Care, International Islamic University Malaysia, Jalan Hospital, 25100 Kuantan, Pahang, Malaysia

Abstract

Post-traumatic parotid sialocele is a subcutaneous extravasation of saliva from the parotid gland secondary to traumatic disruption of its duct or parenchyma. Currently, there is no consensus regarding the best therapy for parotid sialocele, as it is resistant to conservative management. The present paper puts forward a relatively simple, safe and effective technique for the treatment of parotid sialocele, specifically a peroral drainage technique. The results justify our recommendation to use this approach for the treatment of sialocele.

Keywords: trauma, parotid, surgery, drainage, salivary duct

Introduction

A sialocele is often initially managed conservatively, including through repeated aspirations and compression dressings, and this treatment modality proves curative in many cases (1). Resistant cases require surgical treatment, and different surgical approaches to treat parotid sialocele have been described in the literature depending on the location of injury (2,3). Many of the surgical treatment approaches that have been described are complicated, however, and they sometimes require specialised skills and techniques. Furthermore, the results are often inconsistent (2,3). Here, we describe a simple technique of peroral drainage that was successful in a patient with a traumatic parotid sialocele; there was no recurrence after two years.

Case Report

A 53-year-old woman was involved in a car accident and sustained a 10 cm laceration of the left cheek. She presented with a left parotid region swelling two months after the injury. The swelling measured 12 cm in length and 5 cm in width; it was non-tender on bimanual palpation, cystic in nature and consisted of a single locule (Figure 1). No facial weakness was noted. Examination

of the oral cavity showed fullness of the left buccal mucosa. The orifice of Stensen's duct was identified, but milking the swelling failed to produce any material. Probing of the duct was unsuccessful, as the probe came to a soft stop 5 mm from the orifice. The swelling was aspirated and the biochemical report confirmed that the fluid was consistent with saliva. A diagnosis of post-traumatic parotid sialocele was made in light of the history and biochemical findings.

Over the next three weeks, the patient was managed by multiple aspirations and compression dressings; however, the swelling quickly reappeared. Later, the swelling became larger, causing the patient a lot of discomfort and anxiety. The patient was taken to the operating room for per-oral drainage under general anaesthesia. A stab incision was made in the left buccal mucosa at the most prominent bulging area, which was just anterior to the Stensen's duct orifice (Figure 2a). A 5.0 mm sinuscopy trocar cannula (Karl Storz, Tuttlingen, AG) was used to penetrate into the sialocele, using the controlled traction technique (Figure 2b). Once the tip of the trocar was inside the cavity, the metal cannula was advanced a little further, and the trocar was removed. An extension tube from a brachial plexus set (Plexufix, B Braun,

Melsingen, AG) (Figure 3) was inserted into the sialocoele via the metal cannula. The cannula was then withdrawn, leaving the soft plastic tube in the cavity (Figure 2c). Fifty millilitres of viscous fluid consistent with saliva were suctioned out via the catheter. One centimetre of the tube was left in the sialocoele cavity. The end of the tube in the oral cavity was cut into a 0.5 cm flange (Figure 3), and each side was sutured to the buccal mucosa with a 4/0 Dafilon to prevent dislodgement (Figure 2d). The drain was removed three weeks later after a complete resolution of the swelling. The patient was given oral Augmentin (penicillin and clavulanic acid) for five days and antiseptic mouthwashes for the duration the tube was in place. The patient has remained asymptomatic, with no recurrence of swelling after 30 months.

Discussion

A sialocoele should be first managed conservatively, with repeated aspirations and compression dressings (1). Resistant cases require surgical treatment, and different surgical approaches to treat parotid sialocoele have been described in the literature depending on the location of the injury (2,3). The techniques can be divided into three groups; microsurgical anastomosis of the duct, suppression of salivary gland secretion, and diversion of salivary flow into the mouth (1–5). Most of the above procedures are invasive; they require specialised surgical skills, with variable and often poor success rates.

A technique of peroral catheter drainage has been previously described, and almost all the authors reported excellent results in their patients (4–7). Demetriades reported the largest series to date, and showed a success rate of 92% in 12 cases (7). In his technique, a small skin incision is made at the facial scar over the sialocoele, through which a small forceps is used to enter the cyst and puncture into the oral cavity. Using the forceps, a catheter is then introduced into the cyst via the oral cavity and secured to the oral mucosa, and the skin incision is closed with a single suture. We used a sinuscopy trocar cannula to puncture the sialocoele from within the oral cavity, which we considered safe for a large palpable cyst like that in the present case. This spared us from an external approach via a skin incision, as sometimes a thick scar and fibrotic tissue may complicate the access into the cyst. Insertion of the drain can be done via the trocar cannula, which is simple and efficient. The drain is anchored in such a way as to allow for better fitting to the buccal mucosa, while at the

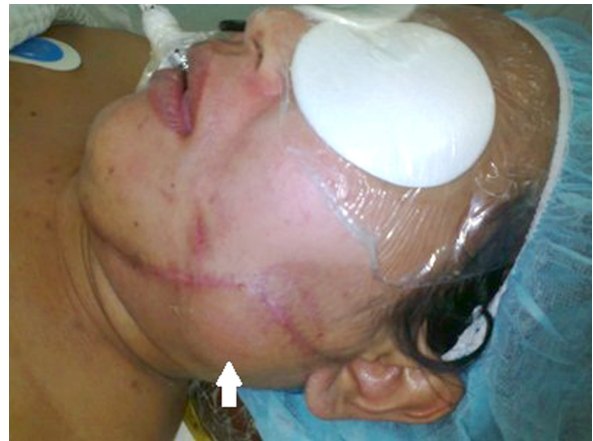

Figure 1: Photograph of the patient showing a laceration scar across the left cheek extending from the left ear to the mandible with a large swelling on the parotid region (white arrow).

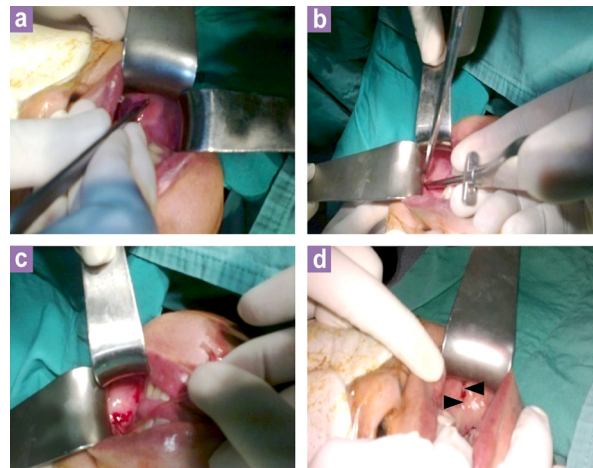


Figure 2: Illustration of the procedure performed. (a) Stab incision over the most prominent bulge of the buccal mucosa. (b) sinuscopy trocar-cannula penetrates into the cyst cavity using counter traction method. once in place, the trocar is removed, leaving the metal cannula inside. (c) the tube catheter is inserted via the metal cannula into the cyst cavity, and the metal cannula is withdrawn. (d) the tip of the tube catheter is cut into a flange, both end is sutured to the buccal mucosa (black arrow-head).

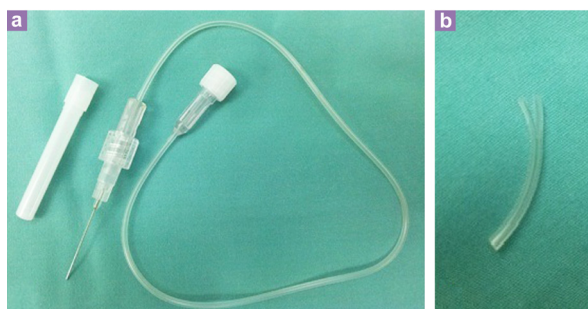

Figure 3: (a) Photograph showing the brachial plexus set. (b) The connector tube is used as a catheter, whereby the tip is cut into a flange and each end is sutured to the buccal mucosa.

same time prevent sensation or interference with chewing.

Based on the experience in managing the present case, we believe that peroral drainage with a tube drain should be considered for the treatment of sialocele. Compared to the more complex procedures, the technique described here is effective, safe and more importantly reduces the risk of injury to the facial nerve.

Acknowledgement

We thank Sr Nadiah Abdul Mubin for her help in editing the figures for this paper.

Conflict of Interest

None.

Funds

None.

Authors' Contributions

Conception and design: ZAA, WIL
Analysis and interpretation of the data and drafting of the article: ZAA
Critical revision of the article for the important intellectual content: ZAA, MSR, AA
Final approval of the article: ZAA, MSR, WIL
Provision of study materials or patient: MSR, MIL, AA
Collection and assembly of data: ZAA, AA

Correspondence

Dr Zamzil Amin Asha'ari
MBBCh (Dublin), MMed ORL-HNS (USM)
Department of Otolaryngology-Head & Neck Surgery
Faculty of Medicine
International Islamic University Malaysia
Jalan Hospital, 25100 Kuantan
Pahang, Malaysia
Tel: +6019 9564 996
Fax: +609 5134 062
Email: zamzilamin@yahoo.com

References

1. Parekh D, Glezeron G, Stewart M, Esser J, Lawson H. Post-traumatic parotid fistulae and sialoceles. A prospective study of conservative management in 51 cases. *Ann Surg.* 1989;**209**(1):105–111.
2. Baurmash HD. Obstructive parotid ductal disease: intraoral management. *J Oral Maxillofac Surg.* 2007;**65**(9):1886–1891.
3. Steinberg MJ, Herrera AF. Management of parotid duct injuries. *Oral Surg Oral Med Oral Pathol Oral Radiol Endod.* 2005;**99**(2):136–141.
4. Edkins O, van Lierop A, Fagan J, Lubbe D. Peroral drainage of post-traumatic sialoceles: report of three cases. *J Laryngol Otol.* 2009;**123**(8):922–924.
5. Sulabha A, Sangamesh N, Warad N, Ahmad A. Sialocele: an unusual case report and its management. *Indian J Dent Res.* 2011;**22**(2):336–339.
6. Canosa A, Cohen MA. Post-traumatic parotid sialocele: report of two cases. *J Oral Maxillofac Surg.* 1999;**57**(6):742–745.
7. Demetriades D. Surgical management of post-traumatic parotid sialoceles and fistulae. *Injury.* 1991;**22**(3):183–184.