

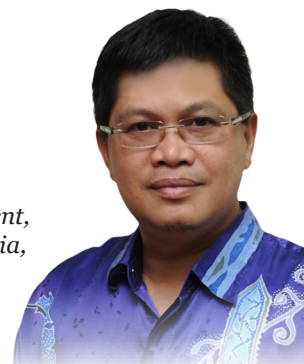Limb Salvage Surgery for Musculoskeletal Oncology

Wan Faisham Nu'man Bin Wan Ismail

Submitted: 2 May 2015

Accepted: 18 June 2015

Orthopaedic Oncology Unit, Orthopaedic Department,
School of Medical Sciences, Universiti Sains Malaysia,
16150 Kubang Kerian, Kelantan, Malaysia



Abstract

The management of musculoskeletal tumours has progressed tremendously over the past few decades. Limb salvage surgery has become a standard practise without compromising the oncological outcome. Patients generally will benefit with superior function and a better quality of life compared with definitive amputation. The multidisciplinary approach and advancement of surgeries are important to achieve patient survival and optimum function.

Keywords: limb salvage, sarcoma

The management of malignant bone and soft-tissue sarcoma has been established in our country for the past two decades. Surgical management, primarily amputation, and the role of chemotherapy are widely practised by general orthopaedic surgeon. The heterogeneity of this tumour always complicates its management and results in inadequate optimum treatment. The advancement of the knowledge of the disease process and technology results in better local control and increased patient survival. These problems should be treated at centres using a multidisciplinary approach with an oncology surgeon, musculoskeletal radiologist, pathologist and oncologist for better care (1).

Limb-sparing surgeries for patients with primary malignant sarcomas of the extremities are now well established. Advances in orthopaedic and plastic surgery, bioengineering, radiotherapy and chemotherapy have all contributed to the development of safer and more reliable surgical techniques. Magnetic resonance imaging (MRI) and computed tomography (CT) scan now provide accurate tumour definition and enhance the possibility of achieving safe surgical margins. The first objective of this type of tumour surgery is to avoid local recurrence, which almost always leads to death. The second objective is to preserve as much function as possible. Amputation may be the only safe surgical option in some patients with extensive skin or neurovascular involvement: a 10% to 15% amputation rate is common. Multidisciplinary management of osteosarcoma has been practised at the Musculoskeletal Oncology Unit of Universiti Sains Malaysia Hospital since 1997. We published the results in

2004 and concluded that limb salvage surgery, compared with amputation for local control of the disease, is justified as a treatment of choice in selected cases of osteosarcoma (2). Recently, in 2015, the overall survival of patients who completed treatment was 43.6% at 5 years, whereas it was 58.2% at 5 years for the limb salvage group. The disease-free survival was 43.6% (3). This result was comparable to those of other centres (1,3) but a significant number of our patients did not complete treatment, leading to poor survival (Figures 1 and 2). Public education and patient compliance remain a major challenge in our practise.

Benign bone tumour management also possesses challenges because it occurs in the young reproductive age group. Aggressive benign tumours such as giant cell tumours (GCTs) of the bone presented with pain, pathological fracture and loss of function. Furthermore, in our patients, the GCT not only presented with locally aggressive behaviour but also had a higher incidence of pulmonary metastases. The aggressive behaviour of a GCT seems to occur in Asian populations more frequently than in other populations (4). Understanding the fundamental science of the disease and its clinical correlation is important to manage the disease with success (5). The future of research, particularly genetic approaches with functional investigation, will provide mechanistic explanations of GCT of the bone genesis and subsequently improve therapeutic approach.

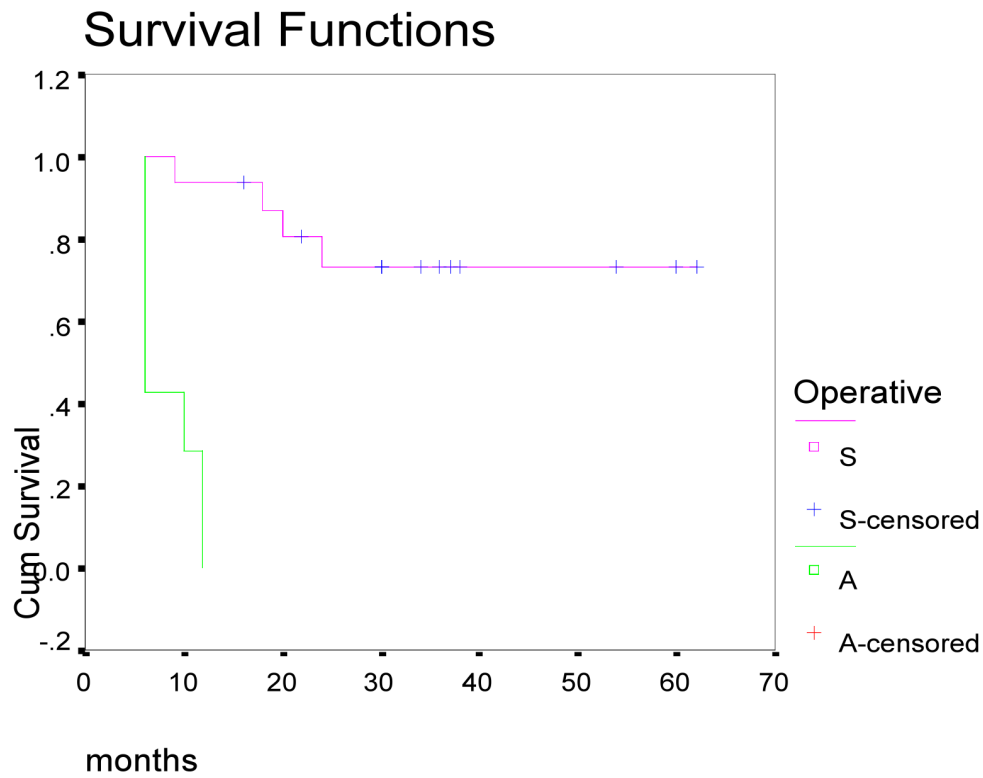


Figure 1: Actuarial survival of 23 patients with osteosarcoma stratified by treatment group of amputation versus limb salvage (2)

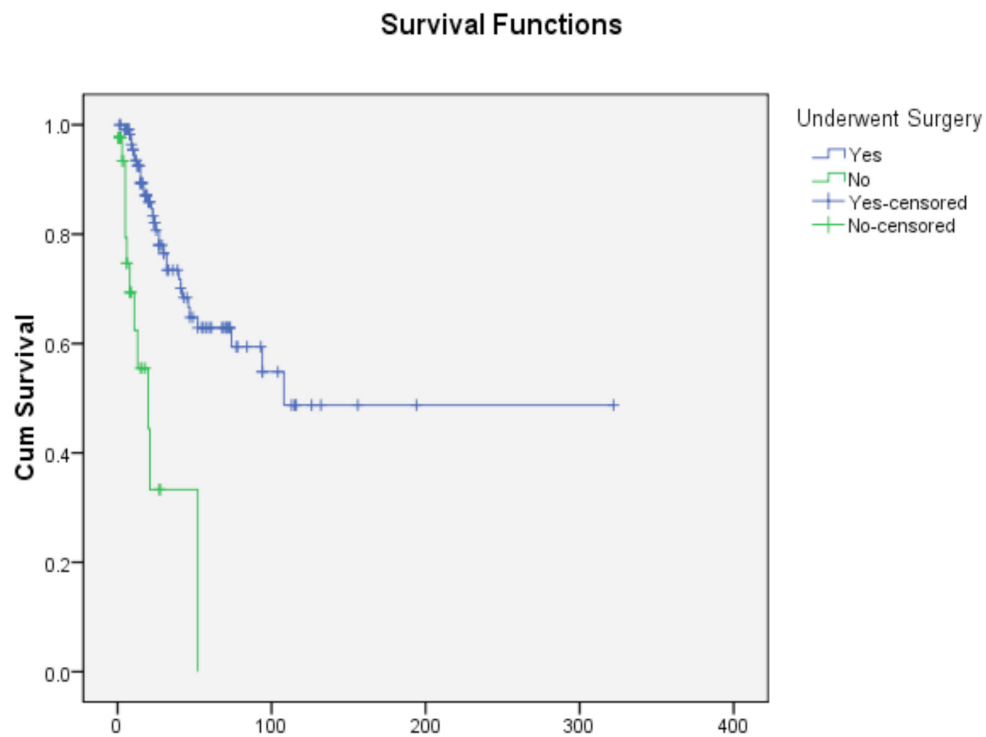


Figure 2: Survival plot for comparison between patients who completed treatment and surgical resection of the primary tumour and patients who did not complete treatment (3)

The local control of soft-tissue sarcoma of the extremity required amputation in the past because of the high local recurrence rate with local resection. At present, limb salvage procedures combined with radiotherapy have allowed local control without amputation. The challenge in our society is delayed presentation with large extra compartment lesion. Resection of these tumours results in massive soft-tissue defects and a higher risk of contamination. Vascularised myocutaneous flap transfer with local brachytherapy, in our experience, produces optimum function and a lower risk of recurrence and surgical complication (6). At present, we can achieve good local control, but the overall survival still needs to be improved.

Mega endoprosthesis replacement for reconstruction of bony defects following tumour resection has shown to produce good early and late functional results (7). Endoprosthesis reconstruction allows immediate weight bearing, maintenance of joint mobility, and early return to activities. Our study on the functional outcome confirmed the above findings. However, the cost of these prostheses is very high and precludes their use in most patients (Figure 3). Modification of the surgical technique with allografts also produces equally good results. Limb salvage surgery in developing countries is always complicated with late presentation and delayed diagnosis.

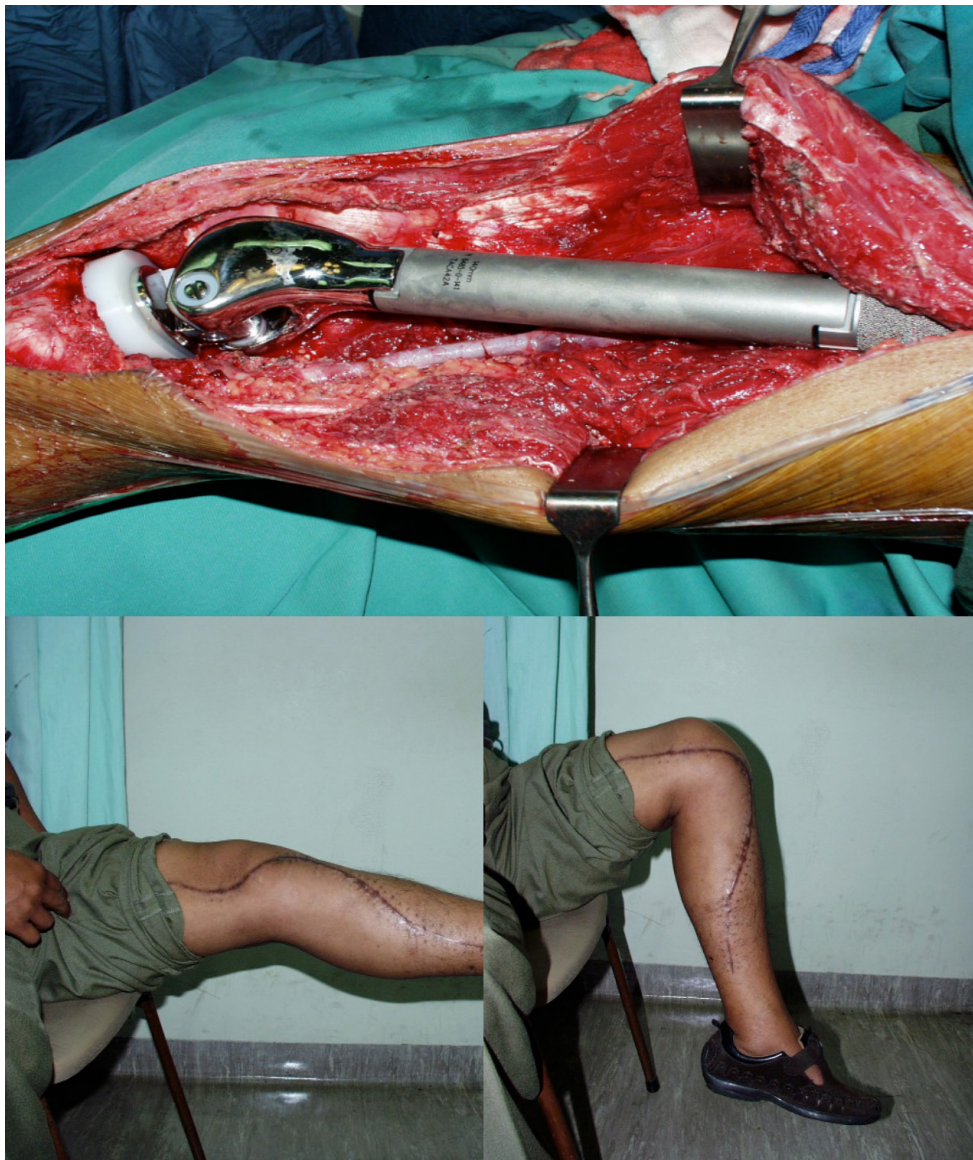

Figure 3: Patient with distal femur endoprosthesis, he has full extension and 90° knee flexion and ambulating pain free. At present he survives for 8 years without disease

At the time of diagnosis, the tumour grows to a large size and involves massive bone and soft tissue. The margin for resection is narrow with a higher risk of recurrence, and the reconstructive soft-tissue procedure with flap transfer is mandatory to minimise complications and to optimise function. Biological reconstruction with vascularised fibula grafts is a good alternative for reconstructing the combination of bone and soft-tissue defects with equally good function. These biological reconstructions are long lasting without problems of late loosening and are considered the best option in young age groups with an active lifestyle (Figure 4) (8). The need for microsurgical expertise and training, however, precludes the use of this technique in most hospitals in Malaysia.

The role of the orthopaedic surgeon in the management of metastatic bone disease is equally important. The goals of treatment are to relieve pain, improve function and ambulation, facilitate medical and nursing care and improve

psychological wellbeing. Aggressive treatment results in the restoration of function and diminution of pain. Multimodality treatment, which includes surgical stabilisation and replacement, radiation, and medical treatment, can preserve limb function, particularly an impending or established fracture. Although the patients' survival outlook has not changed, the quality of life is enhanced significantly.

In general, musculoskeletal tumour treatment in Malaysia is evolving. Most of the patients need to be referred and travel to tertiary hospitals for treatment. More doctors need to be trained in this field and provide services nationwide.

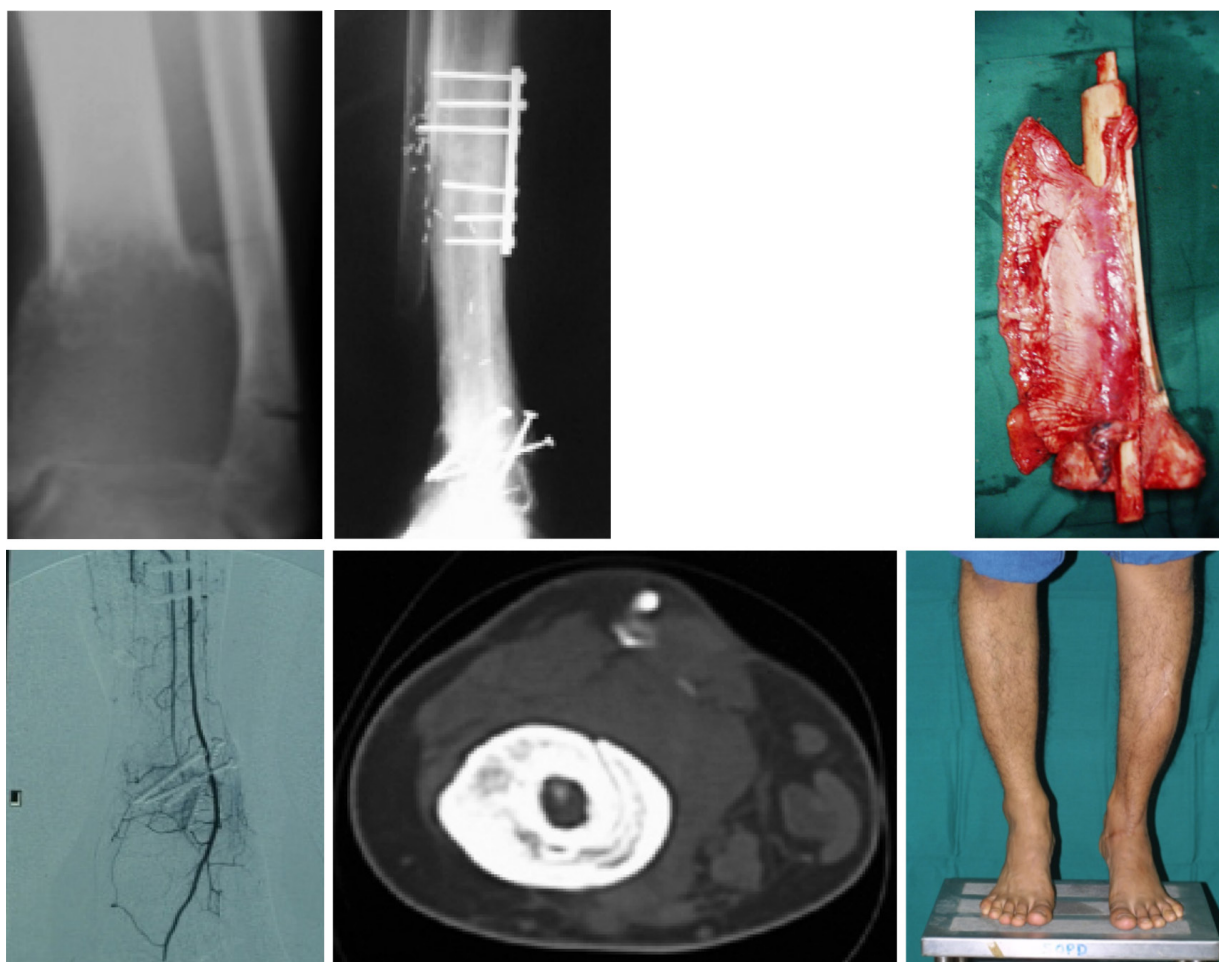


Figure 4: Biological reconstruction with vascularised osteocutaneous fibula flap for reconstruction of aggressive giant cell tumour in young active patient

Correspondence

Prof Dr Wan Faisham Nu'man Bin Wan Ismail
BSc Med (UKM) MD (UKM) M Med Ortho (USM)
Orthopaedic Oncology Unit
Orthopaedic Department
School of Medical Sciences
Universiti Sains Malaysia
16150 Kubang Kerian
Kelantan, Malaysia
Tel: +609-766 4511
Fax: +609-766 4510
Email: faisham@usm.my

References

1. Bielack SS, Kempf-Bielack B, Delling G, Exner GU, Flege S, Helmke K, et al. Prognostic factors in high-grade osteosarcoma of the extremities or trunk: An analysis of 1702 patients treated on neoadjuvant cooperative osteosarcoma study group protocols. *J Clin Oncol.* 2002;**20(3)**:776–790. doi: 10.1200/JCO.20.3.776.
2. WI Faisham, Zulmi W, Halim AS, Biswal BM, Mutum SS. Osteosarcoma: The outcome of limb salvage surgery. *Med. J. Malaysia.* 2004;**59 Suppl F**:24–34.
3. Faisham WI, Mat Saad AZ, Alsaigh LN, Nor Azman MZ, Kamarul Imran M, Biswal BM, et al. Prognostic factors and survival rate of osteosarcoma: A single institution study. *Asia Pac J Clin Oncol.* 2015. doi:10.1111/ajco.12346.
4. Sung HW, Kuo DP, Shu WP, Chai YB, Liu CC, Li SM. Giant cell tumour of bone: Analysis of two hundred and eight cases in Chinese patients. *J Bone Joint Surg.* 1982; **64A**:755–761.
5. Faisham WI, Ng TP, Norazman MZ, Zulmi W, Salzihan MD, Mutum SS. p53 expression Immunohistochemistry index in stage III giant cell tumor of the bone. *JMED Res.* 2014;**2014**. doi:10.5171/2014.675393.
6. Biswal BM, Ruzman NI, W Zulmi, Faisham WI, Halim AS. Peri-operative brachytherapy in soft tissue sarcomas: Hospital USM experience. *Internet J Oncol.* 2009; **7(2)**.
7. Shahril AR, Nawaz AH, Nur Azman MZ, Zulmi W, Faisham WI. Early functional outcome of resection and endoprosthesis replacement for primary tumor around the knee. *Malays Orthop J.* 2013;**7(1)**. doi: 10.5704.MOJ.1303.013.
8. Halim AS, Chai SC, Azman WS, Mat Saad AZ, Faisham WI. Long term outcome of free fibula osteocutaneous flap and massive allograft in the reconstruction of long bone defect. *Ann Plast Surg* (in press).